

LETTER TO THE EDITORS

ALLERGIES IN ADOLESCENTS

To the Editors: I really enjoyed reading the letter to the editor 'A survey of the perception of allergies by adolescent school pupils in a Cape Town suburban school' by Caronwen-Joy Potter, in the September/October 2002 edition. It was a pleasant break from the high-powered immunology articles that simple mortals like me have to battle to wade through.

It is also important to note the high incidence of allergic rhinitis in a high school. I am sure this is the same for other high schools. This is a most debilitating problem which is often ignored by health professionals and particularly those who prescribe from hospital pharmacies who do not want to deplete their budgets on non-

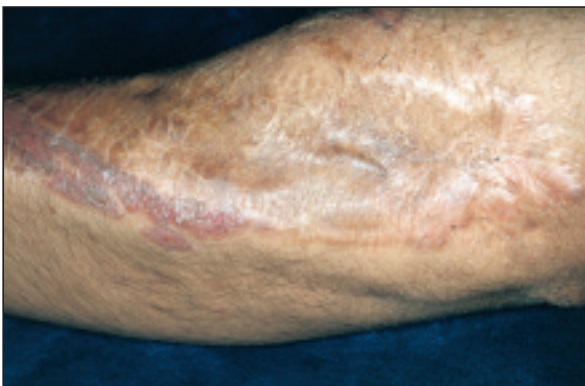
sedating antihistamines. Many medical aids also do not recognise allergic rhinitis as a chronic disease. I personally have seen lives change in children with proper management of this condition.

A Morison

Head: Department of Paediatrics
Victoria Hospital
Private Bag X2
Plumstead
7800

DERMATOLOGY QUIZ

WIN
A
PRIZE!



CLINICAL HISTORY

The patient presented with shortness of breath, tiredness, and an erythematous papulosquamous rash, superimposed on a scar on the right forearm.

Skin biopsy showed epithelioid granulomas.

- What is your diagnosis?
- What further investigations would this patient require?
- What are the other clinical manifestations of the above condition?
- What is the management of this condition?

Submit your answers and stand a chance to win a prize! The first correct answer drawn on 30 April will win R500. Send your answers, together with your name and address to Dermatology Quiz, ALLSA, PO Box 88, Observatory 7935.

Answers, discussion and the winner's name will be published in the next issue.