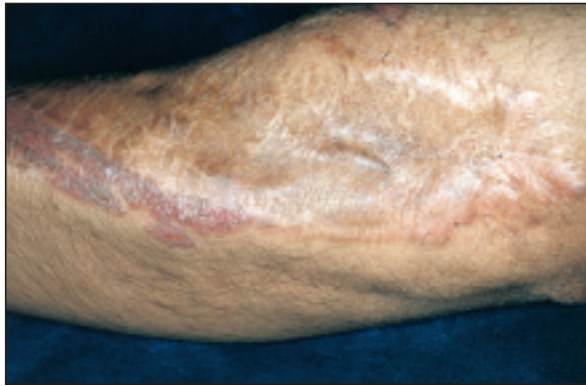


DERMATOLOGY QUIZ ANSWERS

The winner of the R500 prize for the first correct entry drawn for our Dermatology Quiz in the March 2003 issue is Dr ES Benjamin of Gardens, Cape Town. Congratulations!

We're repeating the questions with the answers below.



CLINICAL HISTORY

The patient presented with shortness of breath, tiredness, and an erythematous papulosquamous rash, superimposed on a scar on the right forearm.

Skin biopsy showed epithelioid granulomas.

- What is your diagnosis?
- What further investigations would this patient require?
- What are the other clinical manifestations of the above condition?
- What is the management of this condition?

ANSWERS TO DERMATOLOGY QUIZ, MARCH 2003

Diagnosis: Sarcoidosis

Special investigations: Chest X-ray
SACE (serum angiotensin-converting enzyme)
Serum calcium
Mantoux: negative

Systemic features of sarcoidosis

Polyarthritides: small bones of the hands demonstrate lysis with bone cysts.

Cardiac: granulomatous infiltration

Polymyositis

Nervous system involvement

Ocular: uveitis, iris nodules, orbital involvement

Pulmonary: Acute: hilar lymphadenopathy (in patients with erythema nodosum).

Chronic Pulmonary Disease

Renal

Reticuloendothelial

Liver granulomas

Hypercalcaemia and hypercalcaemia

Cutaneous manifestations of sarcoidosis

Angiolupoid

Annular

Erythema nodosum

Lupus pernio

Maculopapular and erythematous forms

Nodular forms

Papular

Plaque form

Scar sarcoidosis

Subcutaneous sarcoidosis

Atypical forms

Alopecia

Atrophic forms

Erythrodermic sarcoidosis

Hypopigmentation

Ichthyosiform sarcoidosis

Lichenoid

Mucosal involvement - oral and nasal

Nail involvement

Ulcerated sarcoidosis

Verrucous forms

Management

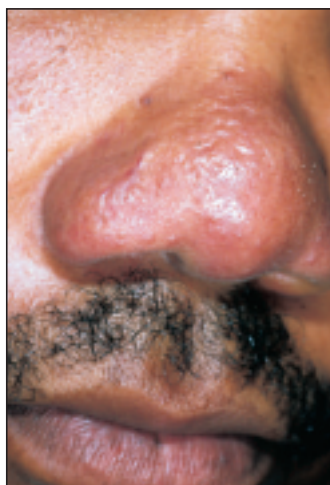Systemic sarcoidosis: Oral steroids for active ocular disease, active pulmonary disease or CNS involvement

Cutaneous sarcoidosis: Steroids:

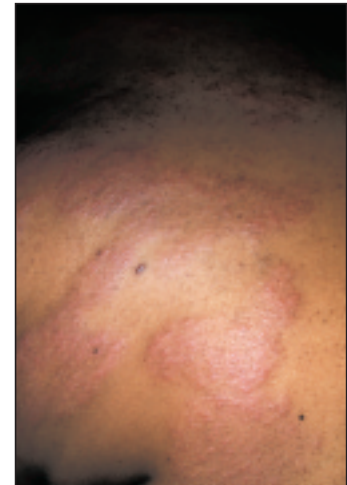- Topical steroids or intralesional triamcinolone 3 mg/ml effective for small lesions
- Systemic: Prednisone for widespread or disfiguring involvement.

Chloroquine 250 mg daily for widespread or disfiguring lesions refractory to intralesional steroid.

The dermatology quiz was compiled by Dr ME Docrat.



Sarcoidosis of the nose (lupus pernio)



Cutaneous sarcoidosis