

ABC OF ALLERGOLOGY

HAY FEVER

Adrian Morris

Allergy Clinic, Constantiaberg Medi-Clinic, Cape Town, South Africa



Spring will soon be upon us and seasonal allergic rhinoconjunctivitis (SAR) will be the allergic disorder most on our minds. SAR affects a hefty 15% of the general population (and up to 50% of adolescents). Although often trivialised, untreated allergic rhinitis can cause a significant impact on quality of life and untreated SAR is more debilitating than asthma.

In 2001, rhinitis nomenclature (Fig. 1) proposed by the Allergic Rhinitis and its Impact on Asthma (ARIA) working group of the WHO superseded the traditional 'Seasonal or perennial classification of allergic rhinitis'. ARIA divides allergic rhinitis into two main categories: intermittent (less than 4 days per week or less than 4 weeks' duration) and persistent (more than 4 days per week and over 4 weeks in duration). Intermittent and persistent allergic rhinitis are further subdivided into 'mild' (minimal symptoms) or 'moderate/severe' (troublesome symptoms, sleep disturbance and impairment of daily activities). In this article we focus on the more severe and persistent end of the allergic rhinoconjunctivitis spectrum which is usually triggered by exposure to common environmental tree and grass pollens (pollinosis).

Symptoms such as intense itching of the nose, eyes, palate, ears and throat with repetitive bouts of sneezing, profuse watery rhinorrhoea and tearing occur when pollen levels exceed 30 grains/m³. Pollen levels may rise above 500 grains/m³ at the peak of the grass pollen season. Occasionally pollen-induced wheezing may occur in the form of hay asthma. The implicated trigger allergens start with a tree pollen 'blip' (oak, plane, acacia and olive) in early spring (August), followed by a long grass pollen 'surge' (Bermuda, rye and Eragrostis) persisting from September through to the end of February. Weed pollens (English plantain and cosmos) rise for a short 'spell' in late summer and mould spores (*Alternaria*, *Cladosporium* and *Epicoccum*) predominate in spring and autumn but tend to be less problematic than pollen grains unless spore counts exceed 3 000/m³.

In South Africa we rarely see the silver birch tree pollen oral cross-reactions which occur with certain fresh fruit such as apple, cherry and hazelnuts (oral allergy syndrome) so often seen in northern Europe.

Essentials of hay fever treatment

Antihistamines: Regular use of antihistamines throughout the pollen season is effective especially if treatment is commenced early in this period. Non-sedating longer-acting antihistamines include fexofenadine, levocetirizine and desloratidine; occasional slight sedation has been attributed to cetirizine, mizolastine and loratidine. Diphenhydramine (Allergex) readily crosses the blood-brain barrier and can cause significant sedation and mood changes although many individuals seem to tolerate it well. Diphenhydramine remains a readily accessible and cheap treatment option and still forms the bulk of OTC (non-prescription) hay fever medication. Topical antihistamines such as levocabastine and azelastine can be used with good results for nasal allergy but are particularly useful in controlling ocular allergies.

Cromones: Sodium cromoglycate eye and nose drops which have been available since the 1970s are more effective in children and have an excellent safety record, but must be used four times a day. Nedocromil sodium eye or nose drops are used twice daily. The new mast cell stabiliser/antihistamine eye drop olopatadine seems highly therapeutic when used twice daily.

Nasal steroids: Aerosol beclomethasone, fluticasone, triamcinolone, mometasone and budesonide reverse chronic nasal inflammation and congestion in established allergic rhinitis. Fluticasone nasules afford excellent nasal penetration if applied in the 'head back' or 'salaam' positions. None of these nasal formulations help ocular symptoms of hay fever. Although highly effective, ocular topical steroids should be used with extreme caution (preferably under the supervision of an ophthalmologist, because of risk of corneal ulceration and cataract formation).

Decongestants: Xylometazoline and oxymetazoline when used topically for short periods (less than 7 days) are effective in reducing nasal blockage and facilitate better penetration of topical steroid nose sprays. Rebound congestion is always a problem if decongestants are used continuously ('rhinitis medicamentosa'). Oral decongestants must be used with caution in hypertension, diabetes, glaucoma and prostatism.

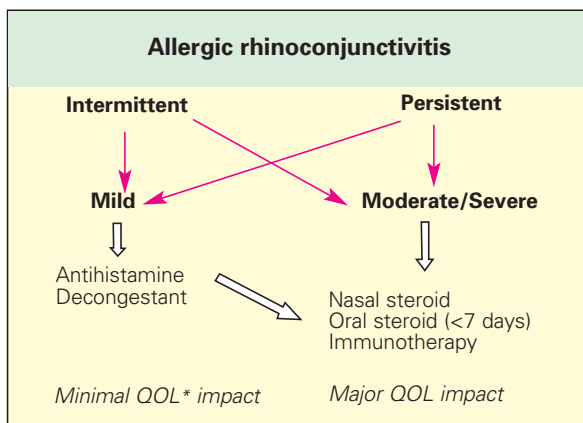


Fig. 1. ARIA Guidelines 2001 * QOL = quality of life issues

Correspondence: Dr A Morris, 112 Constantiaberg MediClinic, Plumstead 7800, Tel 021-797-7980, fax 021-683-5335, e-mail: adrianmorris@absamail.co.za

Essential hay fever treatment

- Antihistamines
- Nasal steroids
- Topical decongestants
- Emergency oral steroids

For the more refractory symptoms

'Steroidophobia' is a major stumbling block to treatment with nasal steroids and patients need a careful explanation as to how important continued low-dose nasal application is to continued symptom control.

Steroid side-effects such as growth retardation, cataracts and osteopenia do not occur at the usual recommended therapeutic dosages, but concomitant inhaled steroid use for asthma should be borne in mind when assessing the 'steroid load'.

A short course of oral steroids, perhaps 20 mg prednisone daily for 5 days will usually unblock even the most resistant nose and give good symptom relief while antihistamines and regular inhaled steroids get to work. This regimen is particularly useful at examination time or for 'special events' such as weddings! However, repeat depot injectable steroids such as Celestone Soluspan and Depo-Medrol (although very effective) should be discouraged for fear of causing unpredictable systemic side-effects (osteoporosis, hypertension, diabetes) and local muscle atrophy.

Commencing regular antihistamine medication up to 4 weeks pre-season has been shown to significantly improve symptom control in refractory hay fever.

Grass pollen specific **desensitisation immunotherapy** (SIT) is the only potentially curative treatment for severe grass pollen allergic rhinoconjunctivitis. Treatment usually spans 3 years and the newer sublingual droplet preparations seem as therapeutic as the injectable vaccines. Disappointingly, this curative treatment marketed in South Africa by ALK-Abello (Laboratory Specialities) has still not received the 'green light' from our national Medicines Control Council. SIT currently has to be arranged on a 'named patient' basis and although a tediously slow process, the end result is well worth the effort.

Xolair (omalizumab), the new monoclonal anti-IgE antibody preparation is an IgE specific therapy for severe asthma and rhinitis, which needs to be given by injection. It is very costly and unlikely to become a first-line treatment option for hay fever.

Aspirin-intolerant individuals with a combination of pollen allergic rhinitis, nasal polyposis and coexistent asthma will benefit from a leukotriene receptor antagonist medication such as montelukast or zafirlukast.

Non-pharmacological treatment

The main impediment to treatment and the cause of suboptimal allergic rhinoconjunctivitis symptom control is the resistance of many patients to using their prescribed nasal steroids and antihistamines. Patients usually fail to use regular doses of medication and as soon as symptoms improve, they allow the treatment to lapse only to become symptomatic again. Uncontrolled allergic rhinitis will adversely affect asthma, making chest symptoms more difficult to control. Patients need constant reinforcement of the safety and efficacy of their prescribed allergy medication.

Alternative or complementary treatments remain extremely popular with the public who experiment with remedies including dilute homeopathic extracts of red onion (allium), eyebright (euphrasia), sabadilla and herbal treatments such as butterbur and sambucos. Another popular remedy is to consume 'local' honey for one month prior to the pollen season. This has been advocated as a form of natural immunotherapy (but never confirmed in any studies). The most extensively

Non-pharmacological measures

Nasal saline douching
Wrap-around sunglasses
Remain indoors / close windows
'Escape' on holiday (to the sea)

investigated of these alternative treatments is butterbur (Petadolex) which has been shown to be as effective as many antihistamines.

Simple non-pharmacological and avoidance measures do help. For example, a simple saline nasal douche or lavage is effective. Saline and seawater nose sprays (Sterimar) help flush pollen grains off the nasal mucosa and improve nasal patency. Wrap-around sunglasses are helpful and occasionally a face and nose mask may be necessary. Monitoring of pollen forecasts and remaining indoors during mid-morning and early evening (when pollen counts peak) will help. An immediate shower and change of clothing after extended outdoor exposure will reduce pollen levels transferred indoors. Additional prophylactic medication may need to be taken on days when pollen counts are excessively high. When travelling by car, be sure to close the windows and put on the air conditioner to filter out pollen. Special pollen-arresting filters and ionisers in the home are expensive and often ineffective.

Pollen calendar for South Africa

August: Tree pollens (oak, plane, acacia and olive)

September to February: Grass pollens (rye, Bermuda and Eragrostis)

March to May: Weed pollens (plantain and cosmos) and mould spores

Specialist referral

Who, what, why and when to refer? The majority of patients can be successfully managed in general practice. ENT specialist referral is necessary if hay fever symptoms are atypical or fail to respond to standard treatments.

Allergen skin-prick testing is always helpful and can alert the hay fever sufferer to specific allergens, especially tree pollen, grass pollen and mould spores and their avoidance. RAST testing is more accessible and specific IgE to aero-allergens can be determined at most state and private pathology laboratories using the UniCAP RAST method. These tests are covered by all the reputable medical aid societies.

Endoscopic nasal surgery does not usually contribute to hay fever symptom control unless an anatomical anomaly is exacerbating symptoms in which case septoplasty, polypectomy or partial turbinectomy procedures may help.

The key to modern hay fever symptom control remains oral and ocular antihistamines with the addition of intranasal steroid sprays, all of which should be used continuously throughout the pollen season if good symptom control is to be achieved.

The author would like to thank Prof Eugene Weinberg for reviewing the manuscript and for his invaluable input.

FURTHER READING AND WEBSITES

ARIA Guidelines. *J Allergy Clin Immunol* 2001;108(5): suppl.

Durham S. *ABC of Allergies*. London: BMJ, 1998.

Morris A. Pollinosis: ALLSA Information Sheet. 2000.

Mygind N. *Essential Rhinitis*. 2nd ed. London: Blackwell, 1995.

- Allergy Society of SA : www.allergysa.org
- BBC Guide to Allergies: www.bbc.co.uk/health/allergy
- Allergy and Allergies Agency: www.allergy-network.co.uk

Image: *The Ladies' Home Journal*