

ALLERGIES IN THE WORKPLACE

EPOXY RESIN EXPOSURE AND DERMATITIS – A CASE STUDY

Anna Fourie, MScMed

*National Institute for Occupational Health,
Johannesburg, South Africa*

Hilary Carman, MB BCh, FFDerm (SA)

*NIOH Dermatology Clinic & private practice,
Johannesburg, South Africa*

Tanusha Singh, MScMed

*National Institute for Occupational Health,
Johannesburg, South Africa*

ABSTRACT

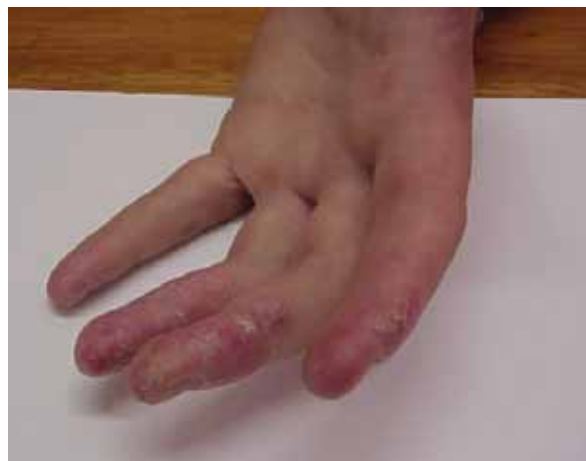Epoxy resins are a well-known cause of occupational contact dermatitis (OCD). A high index of suspicion for allergic or irritant contact dermatitis in workers dealing with these agents should be maintained. The cases presented below highlight some of the complexities of assessing skin reactions to epoxy resins.

INTRODUCTION

Epoxy resins are important raw materials with applications in practically every major industry. They are found in adhesives and glues, laminates, surface coatings, paints and inks, product finishes, vinyl gloves, dental bonding agents, floor coverings and microscopy immersion oil. They are used primarily as two-component adhesive systems comprising an epoxy resin and a curing agent (also called a hardener or catalyst). Some epoxy products also contain additives which may be irritants such as organic solvents, fillers such as fibre-glass or sand, and pigments. Epoxy resin monomers polymerise by cross-linking with the curing agents, or hardeners, to form the final product which is solid. The hardening agents are usually amines or acid anhydrides. These solids have a three-dimensional network. The most commonly used monomer is made by combining bisphenol A and epichlorohydrin to form diglycidyl ethers that vary in chain length. Some epoxies cure in a few minutes at room temperature. Others need additional time or heat to harden.

The cured epoxy resin is non-sensitising. Allergic contact dermatitis (ACD) results from exposure to the uncured resin or to hardeners. Approximately 90% of cases result from sensitisation to the epoxy monomer. The curing agents are responsible for the remainder of cases.¹ Epoxy resins cause more cases of OCD than any other chemical introduced in recent years.^{2,3} Therefore skin exposure to these substances in the workplace should be avoided. Patch testing is used to determine sensitivity to contact allergens, and specific tests to diagnose allergy to epoxy resin chemicals are available at the National Institute of Occupational Health (NIOH).

Correspondence: Ms Tanusha Singh, National Institute for Occupational Health, PO Box 4788, Johannesburg, 2000. E-mail Tanusha.singh@nioh.nhls.ac.za



Contact dermatitis from epoxy resin exposure.

CASES REPORTED

Ten workers who presented with possible work-related skin disease and who had been exposed to epoxy resin were referred to the NIOH for assessment between January and August 2005. Eight workers came from the same company. This company used both quick-setting epoxy and heat-requiring epoxy. These processes result in epoxy vapours which would be present in the factory environment.

Methods

The workers were clinically assessed by means of a clinical and work history, and skin examination. Patch testing was performed on all of the workers. The European standard (ESS) and/or plastic/glue (PG) series were used for testing. The ESS consists of 25 different allergens which are the most frequently encountered causes of allergic contact dermatitis. Among these is epoxy resin which would pick up sensitisation in workers exposed to the chemical. In the plastics, glues and epoxy series in use at the time there were 7 other possible allergens found in epoxy resins; the newer series available at NIOH now has 9 other allergens.

Patch testing

Workers were referred for patch testing by occupational health practitioners at the companies where they work and by dermatologists. Patch tests were not done on workers with acute widespread dermatitis or those on oral steroids. The allergens used were obtained from Chemotechnique Diagnostics (Malmö, Sweden) and Trolab Hermal (Reinbeck, Germany) and included the European standard and plastic, glues and epoxy series of patches as well as substances obtained from the workers' respective workplaces. Patch testing was performed with IQ chambers from Chemotechnique and left in place for 3 days. They were read between 15 and 30 minutes after removing the patches. Ideally patches should be left in place for 48 hours, removed, the results read and the reading repeated after another 24 or 48 hours. This allows for differentiation between allergic and irritant reactions since an irri-

tant reaction fades by 72 hours. For practical reasons the patches were read only once, after 3 days.

Patients were instructed to remove the patches if they developed a severe reaction before the second visit and to note exactly where the patches had been placed. The reactions are graded as shown in Table I.

Table I. Interpretation of patch test reactions

Grade	Reaction	Appearance
-	Negative	Normal
?	Questionable	Erythema
1+	Weak	Non vesicular with erythema and papules
2+	Strong	Vesicular or oedematous
3+	Extreme	Spreading, bullous or ulcerative
IR	Irritant	Glazed, 'burned appearance', pustular, edge effect

Results

Results are shown in Table II.

Clinical presentation

A careful work history confirmed that all workers were employed in factories in which epoxy resins were used.

All the workers complained of itch and/or a burning sensation of the skin. Eight workers presented with dermatitis (redness, swelling, blistering, weeping, scaling and thickening of the skin). One worker presented with swelling and redness of his eyes and lips which was typical of urticaria. The tenth worker presented with patchy loss of pigmentation known as leucoderma. The distribution of the rash, namely on the hands, arms, neck, body and face suggested that the workers were exposed to dusts and vapours containing the sensitising agents, as well as known direct skin contact.

Patch testing

- Four of the workers had definite reactions (1-2+) to epoxy resin included in the European standard series. This confirmed true allergy.
- A further 3 workers had questionable reactions (?) to the same allergen, indicating possible allergic reactions. Workers were also tested with relevant allergens from the plastic and glues series but these were negative.
- Four of the workers reacted to epoxy-based substances from the workplace.
- One of the workers developed mild irritant reactions to workplace substances.
- Worker No. 7 complained of swelling of the eyes and lips immediately after entering the workplace area which is consistent with an acute urticaria.
- Worker No. 9 presented with leucoderma (resembling vitiligo) around the eyes and on the neck.

DISCUSSION

From the results it can be seen that exposure to epoxy in these workers caused occupational contact irritant and allergic dermatitis, urticaria and leucoderma. Symptomatic workers who are exposed to epoxy resins should be assessed by means of a detailed medical work and exposure history, a medical examination and comprehensive allergy testing. The most common

skin reaction in these workers was contact dermatitis which is known to be the most common form of occupational skin disease (OSD).^{4,5} In the cases considered in this study half of those tested had definite reactions to epoxy resins while three others had equivocal reactions. This corresponds with other studies that indicate that epoxy resin is a common cause of ACD.⁶⁻⁸

The questionable reactions indicated possible sensitisation and these workers should be monitored and retested if indicated.

In addition to the ESS the appropriate allergens from the plastic, glues and epoxy series were applied but these were negative. In the newer epoxy series (Chemotechnique) additional allergens have recently become available. These are important as it has been shown that polyamine hardeners such as diethylenetriamine, triethylenetetramine and dimethyloamino propylamine, as well as reactive diluents can also cause allergic reactions.^{7,9}

Therefore potential reactions in patients who may have been allergic to these epoxy chemicals were not detected. It is hoped that the NIOH will shortly acquire these allergens. In addition positive reactions may have been missed since reactions occasionally occur up to 6 to 7 days after application of the patch test.¹⁰

This case study highlights the importance of testing with workplace agents and confirms the findings of other studies.¹¹ In one case the worker tested negative to the epoxy allergens in the commercial series but positive to the workplace substance. In another case epoxy resin allergy was confirmed by a positive reaction to the allergen supplied by the workplace.

The composition of workplace agents may not be identical to the commercially available allergens because of manufacturing variations and different formulations. Tests with workplace substances, however, are problematic as false-negative and false-positive reactions may occur. The substance may be inappropriately diluted or may contain other irritating constituents.

Epoxy resins and many other chemicals used in the workplace (e.g. thinners, mica, and solvents) may cause irritant reactions in workers. Since patch tests identify allergic reactions and are not useful in the detection of irritant reactions the possibility of irritant reactions should be considered in all cases. In the cases described above many workers used thinners to remove cured epoxy from their hands. In an attempt to remove cured epoxy one worker resorted to using sandpaper.

Worker No. 7 complained of an almost immediate swelling of the eyes and lips when entering the work area. This is typical of an urticarial type of response (probably IgE-mediated hypersensitivity reaction). Urticarial reactions are rare but do occur in epoxy-resin-exposed subjects, normally in conjunction with ACD.⁸ This IgE type of reaction is important since it can lead to other occupational disorders such as rhinitis, conjunctivitis and asthma.¹²

An unexpected finding was a case of leucoderma (resembling vitiligo) around the eyes and on the neck of worker No. 9. Several such cases following allergic contact dermatitis to epoxy resin have been documented.^{3,8} Occupational health workers in companies where epoxy resins are used should be aware of this condition.

Since epoxy resin exposure is a common cause of OCD, it is important that the work environment is well controlled and the workers properly protected. The reactions on the face and neck seen in some of the workers demonstrate the importance of vapours and possibly dusts in causing OCD.

Table II. Summary of exposure, clinical findings and patch test reactions for individual cases

Job description	Occupational exposure	Clinical findings	Patch test	
			Allergen	Reaction
1. Encapsulating	Epoxy resin, thinners, mica	Itchy, vesicular rash on arms, neck & around eyes	Epoxy resin (ESS) Potassium dichromate (ESS) Clioquinol (ESS) Fragrance mix (ESS) Epoxy resin (W)	? ? 2+ ? 1+
2. Crane driver	Epoxy resin, mica sheets	Itchy rash on feet, upper body & arms, hyperpigmented areas seen	Epoxy resin (ESS) Fragrance mix (ESS) Epoxy resin (W)	2+ 2+ 2+
3. Process worker	Epoxy resin, thinners, mica	Itchy rash on dorsum of hands, arms & neck	Cobalt Chloride (ESS) Epoxy resin (ESS) Nickel sulphate (ESS)	1-2+ ? 1+
4. Process worker	Epoxy resin, thinners, mica & grease	Itchy rash on neck, face & forearms, swelling of eyes & face	ESS	Neg
5. Armature winder	Epoxy resins, thinners, varnish, Bostik putty, thermosetting tape	Itchy, red rash & dry, scaly skin on inner forearm	ESS Epoxylite (W) Hot potting resin (Part A) (W)	Neg ?IR ?IR
6. Encapsulating	Epoxy resin, thinners, mica, heavy-duty hand cleaner	Itchy rash on dorsum of hands, forearms, neck & eyelids, swelling of eyes	Epoxy resin (ESS) Epoxylite (W)	1+ 1+
7. Encapsulating	Epoxy resin, thinners, mica & grease	Red, swollen eyes & swollen lips, no visible contact dermatitis	Epoxy resin (ESS)	1+
8. Core making	Epoxy resins; powder coating, Heavy-duty hand cleaner	Itchy vesicular rash on palmar & dorsal surface of hands, & web spaces	Epoxy resin (ESS)	?
9. Coil taping	Epoxy resin, thinners, mica	Depigmented areas around eyes & neck (Contact leucoderma)	Epoxy resin (ESS) Nickel sulphate (ESS)	2+ 2+
10. Apprentice pattern maker	Epoxy resin, cold glue, wood, thinners	Dry, scaly, cracked skin on hands, starts as itchy, vesicular rash	Wool alcohols (ESS) Parateritary phenol formaldehyde resin (ESS)	? ?

Reactions: Neg = negative; ? = questionable; 1+ = weak; 2+ = strong; 3+ = extreme; IR = irritant.

Allergens: ESS = European Standard Series; W = substances from the workplace.

Airborne contamination must be controlled through the introduction of adequate ventilation such as local exhaust ventilation.¹³ In addition personal protective equipment should include safety glasses, face shield, and full face respirators depending on the extent of exposure.

Appropriate hand and body protection is required. The glove material should be appropriate for the type of chemical exposure. Latex gloves give good protection against epoxy resins but only fair protection against the hardeners and solvents encountered. Ethyl vinyl alcohol laminate gloves on the other hand provide excellent protection if used within the limits of the breakthrough time. They should be replaced if damaged.¹⁴ Chemical-resistant clothing, including disposable aprons, coveralls, lab coats and sleeves, should also be used.¹³

SUMMARY

Epoxy resins cause dermatitis, both true allergic and irritant, leucoderma and urticaria. Health care workers should be alert to the problems caused by these chemi-

cals and should ensure that all possible cases are fully assessed. It is important that optimum protective measures should be instituted to protect all workers from these potentially dangerous substances.

Declaration of conflict of interest

The authors declare no conflict of interest.

REFERENCES

- Marks J, Elsner P, DeLeo V, eds. *Contact & Occupational Dermatology*. 3rd ed. Chapter 5 (Standard Allergens). St Louis: Mosby Inc, 2002.
- Rietschel R, Fowler J, eds. *Fisher's Contact Dermatitis*. 4th ed. Chapter 29 [Plastic (Synthetic Resin) Dermatitis]. Baltimore: Williams & Wilkins, 1995.
- Bray PG. Epoxy resins. *Occup Med* 1999; **14**: 743-758.
- Gawkrodger DJ. Patch testing in occupational dermatology. *Occup Environ Med* 2001; **58**: 823-828.
- Chew AL, Maibach HI. Occupational issues of irritant contact dermatitis. *Int Arch Occup Environ Health* 2003; **76**: 339-346.
- Jappe U, Geier J, Hausen BM. Contact vitiligo following a strong patch test reaction to triglycidyl-p-aminophenol in an aircraft indus-

- try worker: case report and review of the literature. *Contact Dermatitis* 2005; **53**: 89-92.
7. Geier J, Lessmann H, Hillen U, *et al*. An attempt to improve diagnostics of contact allergy due to epoxy resin systems. First results of the multicentre study EPOX 2002. *Contact Dermatitis* 2004; **51**: 263-272.
 8. Kanerva L, Pelttari M, Jolanki R, Alanko K, Estlander T, Suhonen R. Occupational contact urticaria from diglycidyl ether of bisphenol A epoxy resin. *Allergy* 2002; **57**: 1205-1207.
 9. Jolanki R, Kanerva L, Estlander T, Tarvainen K, Keskinen H, Henriks-Eckerman ML. Occupational dermatoses from epoxy resin compounds. *Contact Dermatitis* 1990; **23**: 172-83.
 10. Jonker MJ, Bruynzeel DP. The outcome of an additional patch-test reading on days 6 or 7. *Contact Dermatitis* 2000; **42**: 330-335.
 11. Ormond P, Hazelwood E, Bourke B, Lyons JP, Bourke JF. The importance of a dedicated patch test clinic. *Br J Dermatol* 2002; **146**: 304-307.
 12. Kanerva L, Jolanki R, Tupasela O, *et al*. Immediate and delayed allergy from epoxy resins based on diglycidyl ether of bisphenol A. *Scand J Work Environ Health* 1991; **17**: 208-215.
 13. *Epoxy Resin Systems Safe Handling Guide* 1997 [cited 2007/05/25]; Available from: http://www.plasticsindustry.org/about/epoxy/epoxy_guide.htm.
 14. Health and Safety Executive. *An Assessment of Skin Sensitisation by the Use of Epoxy Resin in the Construction Industry*. Research Report 079, 2003. Granta Park, Cambridge [cited 2007/05/25]; Available from: <http://www.hse.gov.uk/research/rrpdf/rr079.pdf>

Managing the Allergic Patient

John H. Krouse, MD, PhD, M. Jennifer Derebery, MD and Stephen J. Chadwick, MD
2008, hardcover, 400 pp, 300 illus., 265 x 195 mm, R1 800


This new reference provides up-to-date, disease-specific diagnostic and treatment protocols in a new, full-colour, heavily illustrated reference. This is the most current allergy management information at your fingertips – regardless of your medical specialty.

Key Features

- Get the most up-to-date guidance from the most trusted experts in the field.
- Quickly locate key anatomy, tests, and management protocols in the clinical setting.
- Find everything you need in one place with diagnosis and management included in each chapter.
- Compare common presentations and quickly reference the latest in diagnosis and treatment options with over 300 clinical and diagnostic algorithms, photographs, charts, and tables.

Contents

1 – Introduction to Allergy. 2 – Principles of Allergy Management. 3 – Management of the Patient with Rhinitis. 4 – Management of the Patient with Rhinosinusitis. 5 – Management of the Patient with Asthma. 6 – Management of the patient with Ocular Allergy. 7 – Otitis Media: Background and Science. 8 – Management of the Child with Otitis Media. 9 – Management of the Patient with Inner Ear Allergy. 10 – Management of the Patient with Laryngitis. 11 – Management of the Patient with Drug Allergy. 12 – Management of the Patient with Occupational Allergy. 13 – Management of the Patient with Atopic Skin Disease. 14 – Managing the Allergic Child. 15 – Management of the Patient with Anaphylaxis.



Allergy 3/e


Stephen T. Holgate and Lawrence M. Lichtenstein

August 2006, hardback, 448 pp, 450 illustrations, Mosby, R1 700

This comprehensive, clinically oriented full-colour resource offers you a wealth of detailed information on the diagnosis, treatment, and management of allergic diseases—from asthma to urticaria. Thoroughly updated to reflect today's knowledge, this edition features all of the latest developments in allergy and immunology. Plus, a consistent, logical organization puts vital information at your fingertips.

Features

- Features abundant algorithms that provide at-a-glance assistance in identifying the allergic conditions.
- Offers in-depth information in a chapter dedicated entirely to asthma.
- Valuable treatment protocols assist in prescribing appropriate therapies and effective management
- Includes extensive references that point the way to the key works in the literature.
- Features a new detailed chapter on pediatric allergy, an increasingly common condition.
- Includes a CD-ROM containing all of the illustrations from the book downloadable into PowerPoint™.



Orders: Medical Book Seller, PO Box 3784, Tygervalley 7536

Tel Jackie: 083 303 8500, fax (021) 975-1970,

E-mail: jackie@medbookseller.co.za