

## SKIN FOCUS

**ME Docrat** MB ChB, MMed (Derm),  
Dermatologist, Wale Street Chambers, c/o Wale and  
Long Streets, Cape Town, South Africa

### EYELID DERMATITIS – CLINICAL ASSESSMENT AND MANAGEMENT

Although the focus of this article is eyelid dermatitis, there are other skin conditions that may also occur in the periorbital region. These include seborrhoeic dermatitis, psoriasis, vitiligo and viral and bacterial infections. Clinical photographs of some of these conditions have been included (Figs 1-9).

Although eyelid dermatitis is common in atopic patients, one needs to exclude allergic and irritant contact dermatitis by history, clinical examination and patch testing. Most eyelid dermatitis occurs against a

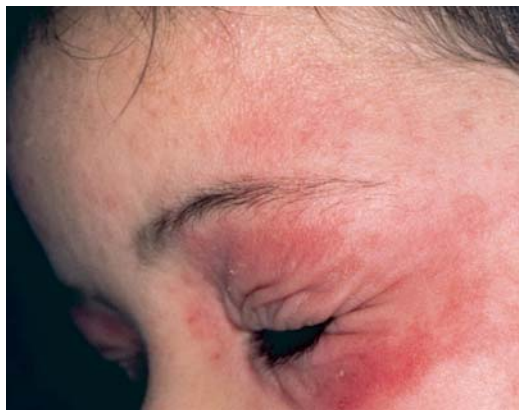

Fig. 1. Childhood eyelid atopic eczema involving the upper and lower eyelid.

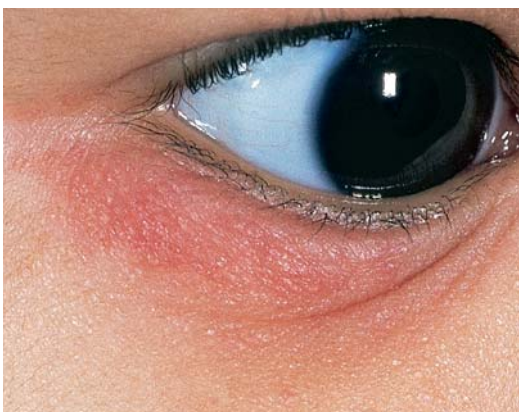

Fig. 2. Lower eyelid eczema in a child.

background of atopy and there is a female preponderance. Although atopic dermatitis may occur on both the upper and lower eyelids, involvement of the upper eyelid alone is usually suggestive of atopic dermatitis.

Contributory factors include exposure to environmental elements such as dry weather and wind. Exposure to irritants may compound the problem. Because skin on the eyelid is extremely thin, percutaneous permeability is enhanced. This results in increased sensitivity which makes the eyelid prone to dermatitis. In patients with chronic eyelid dermatitis, the stratum corneum barrier is breached and oedema and lichenification occur. In some patients, severe lichenification and oedema may cause ectropion and constant tearing. Rarely atopic dermatitis may be associated with ocular complications such as vernal conjunctivitis, keratoconus and cataract. Atopic eczema patients are prone to infection with herpes simplex (eczema herpeticum) and this may involve both the skin and eye. Ocular involvement can lead to corneal scarring and blindness. Prompt treatment with antiviral agents can prevent serious sequelae.

When a patient presents with eyelid dermatitis, the history provides important clues in differentiating the types of dermatitis. The following questions help us in our assessment:

1. What is the duration of the dermatitis? Longstanding eyelid dermatitis which is intermittent is usually atopic. The longer the duration of the eyelid dermatitis, the more unlikely it is to be allergic contact dermatitis. Severe, sudden-onset (short-duration) eyelid dermatitis is usually due to allergic contact. However, weak allergens (e.g. fragrances in cosmetics) may cause long-term rashes.
2. Where did the dermatitis begin? Although involvement of the upper eyelid alone is usually due to atopic dermatitis, atopic patients can have both upper and lower eyelid dermatitis. Allergic contact dermatitis usually occurs on both the upper and lower eyelid.
3. Are there any other body areas affected by dermatitis? Dermatitis on the flexures such as the antecubital region corroborates the diagnosis of atopic dermatitis. Many patients with atopic dermatitis have sparing of the nasal region (head-lamp sign).
4. Is there any history of atopy such as atopic dermatitis, asthma or hay fever?
5. What ocular preparations has the patient been using? If there is recent history of application of eye products such as contact lens solution, antibiotics or local anaesthetic, this may suggest allergic contact dermatitis. Also, has the patient used any new cosmetic products? Irritant contact dermatitis may occur from new cosmeceuticals containing alpha hydroxy acid, and vitamin A or retinoid cream.
6. What environmental factors could be involved? The patient should be questioned about his or her total environment: house, work and hobbies. Eyelid dermatitis in a patient with hobbies such as carpentry (use of glues) or painting may be due to exposure to epoxy resin. Occupational history is important, e.g. allergic contact dermatitis on the eyelids in a dentist may be due to Caine mix.

Correspondence: Dr ME Docrat, Wale Street Chambers, c/o Wale and Long Streets, Cape Town 8001. Tel 021-423-3180/90, e-mail medocrat@intekom.co.za

### **Eyelid dermatitis due to contact allergy**

Allergens affecting the face may initially produce an eyelid dermatitis, as the skin of the eyelids is thin, sensitive and may be contaminated by the fingers (e.g. nickel), by airborne droplets (e.g. fragrance sprays), or by volatile substances (e.g. epoxy resin). On the face allergic contact dermatitis often presents around the eyes with erythema, scaling and peri-orbital oedema. Allergic contact dermatitis from permanent and semi-permanent hair dyes is usually localised on the face (including the eyelids) rather than on the scalp itself. The peri-orbital oedema may be profound and may be mistaken for angioedema (urticaria). However angioedema is not associated with any cutaneous scaling or eczematous changes. This clinical picture may also follow exposure to poison ivy.

The sources of allergens which cause eyelid dermatitis include eye cream, eye shadows, mascara and eye make-up removers, as well as face and hair products. The formaldehyde releasers include quaternium 15, imidazolidine urea, Kathon G and bronolol. The non-formaldehyde releasers include parabens and thiomersal (eye products). Chemicals such as 5-chloro-2-methyl-4-isothiazolin-3 (Kathon G) is one of the most commonly used preservatives found in shampoos and household products.

Eyelid dermatitis may be caused by sensitisers found in eye drops and ointments. These include local anaesthetics, antihistamines, beta-blockers, anticholinergics, neomycin and sulphonomide antibiotics. Neomycin sulphate is a broad-spectrum antibiotic often used in combination with corticosteroids. Because of its combination with a topical steroid, the allergic reaction may be suppressed and go unrecognised.

Eyelid dermatitis may also occur as a result of contact lens fluid containing benzalkonium chloride and thiomersal.

### **Cosmetics**

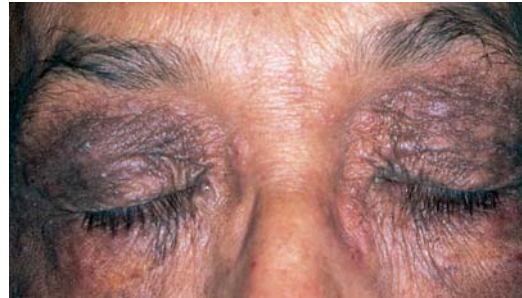Eyelid dermatitis caused by nail varnish may be due to direct contact with the nails or due to the volatile nature of the nail varnish. Contact allergens found in nail polish and nail hardeners include toluenesulphonamide and formaldehyde resin. Sesquiterpene lactone found in composite flowers (arnica, chrysanthemum and camomile) used in cosmetics and skin ointments is another possible irritant. In addition primin may cause airborne contact allergy involving the eyelids. Recently the cosmetic industry has tried to eliminate known sensitisers and irritants. However, preservatives have a role in preventing the overgrowth of bacteria in water-based products. These preservatives may occasionally cause allergic contact dermatitis.

### **Patch testing**

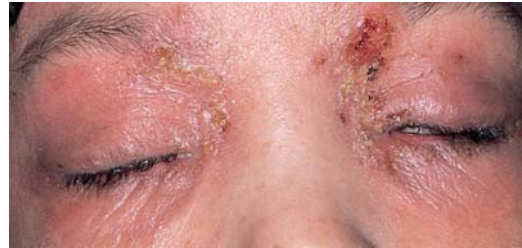Patch testing for contact allergens is essential for specific identification of positive agents. 'Leave-on' products such as cosmetics and perfumes may be applied full strength. Cleansing products may be diluted to 10%. Mascara is often irritant and should be applied on the second visit, having been applied to a chamber at the first visit and left to evaporate. Successful therapy depends on the avoidance of contact with specific allergens.

### **Therapy**

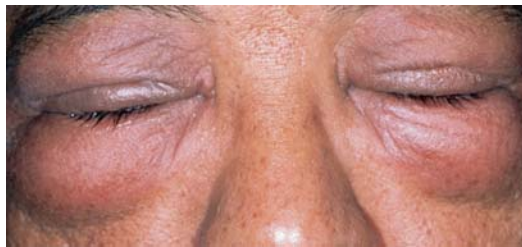The aim of treatment is to decrease the trigger factors and pruritus, suppress inflammation and lubricate the eyelid skin. Acute exudative eyelid dermatitis may be treated with cool compressors or ice packs four times



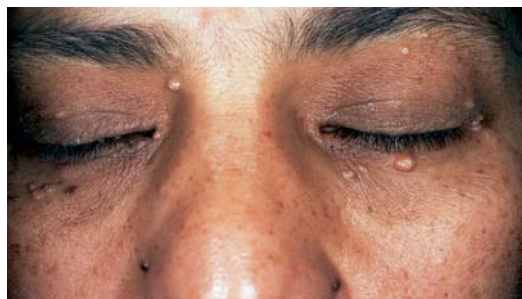*Fig. 3. Chronic lichenified eczema.*



*Fig. 4. Eyelid eczema with secondary impetiginisation.*



*Fig. 5. Contact dermatitis of the eyelid presenting as periorbital oedema.*



*Fig. 6. Molluscum contagiosum may occur in patients with underlying atopic eczema.*

a day. The most important therapeutic tool in the management of acute eyelid dermatitis is the use of mid-potency topical steroids such as mometasone furoate (Elocon), methylprednisolone aceponate (Advantan) and clobetasol butyrate (Locoid). These mid-potency steroids may be used for short periods only (approximately 3 days). Frequent use of soothing and bland emollient ointments (white soft paraffin/Vaseline, SBR Lipocream, Epizone E, Physiogel) is helpful. More severe eyelid dermatitis may be treated with a short course of oral steroids (prednisone 60 mg for 5 days). One should avoid long-term use of topical cortico-

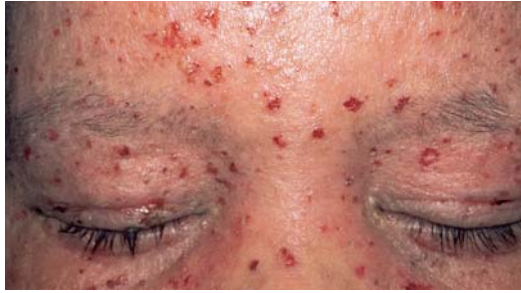


Fig. 7. Herpes simplex on the eyelid superimposed on atopic eczema.

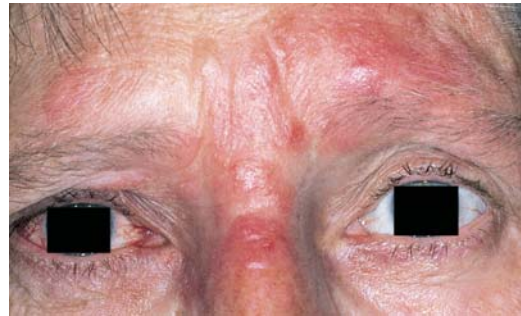


Fig. 9. Contact dermatitis due to neomycin-containing eyedrops.

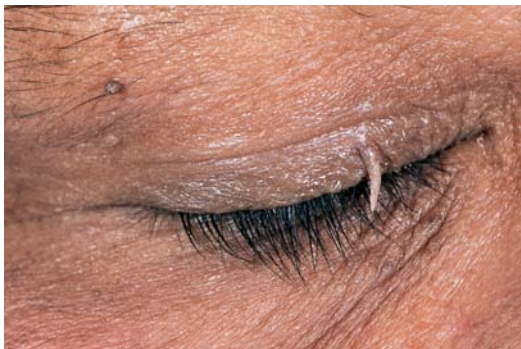

Fig. 8. Cutaneous horn (verruca) in a patient with eyelid eczema.

steroids (even the mild agents that do not contain 1% hydrocortisone) for eyelid dermatitis because of the danger of side-effects such as atrophy, bruising and peri-orbital and acneform rash. Long-term steroid use may also result in dependency and tachyphylaxis. Cessation of the topical steroid may lead to regular rebound. Systemic antihistamines such as hydroxyzine (Aterax) may alleviate the pruritus. The above-mentioned treatment is required for acute eyelid dermatitis, whatever the cause, including atopic dermatitis (where one may get sudden flare-ups), allergic contact dermatitis or irritant dermatitis.

In allergic dermatitis, the key to successful management is the avoidance of further contact with the allergens. Patch testing identifies the causative allergens.

One needs to avoid long-term use of topical corticosteroids in the management of chronic eyelid dermatitis because of the side-effects. The introduction of the non-steroid immunomodulators such as pimecrolimus and tacrolimus (Elidel) has provided us with an excellent armamentarium for the management of this difficult condition. Pimecrolimus and tacrolimus are used to prevent flare-up of peri-orbital atopic dermatitis, thus decreasing or eliminating the use of topical steroids.

If patients develop steroid-induced acneform rash/rosacea around the peri-orbital region, one may prescribe oral antibiotics including lymecycline, doxycycline or minocycline. It is important to explain to patients who have used topical steroids in the long term that withdrawal of the topical steroid will lead to a rebound which may resolve after many months. The application of soothing emollients including Vaseline is extremely helpful. Finally, it is imperative that topical steroids are not used in the long term in management of peri-orbital dermatitis.

#### BIBLIOGRAPHY AND FURTHER READING

- Marks R, ed. Atopic dermatitis (chap 6). In: *Eczema*. London: Martin Dunitz, 1992: 77-97.
- Marks R, ed. Allergic contact dermatitis. (chap 7). *Eczema*. London: Martin Dunitz, 1992: 103-125.
- Champion RH, Burton JL, Burns DA, eds. *Rook, Wilkinson, Ebling Textbook of Dermatology*, vol.2. Oxford: Blackwell Science, 1998: 756-784.